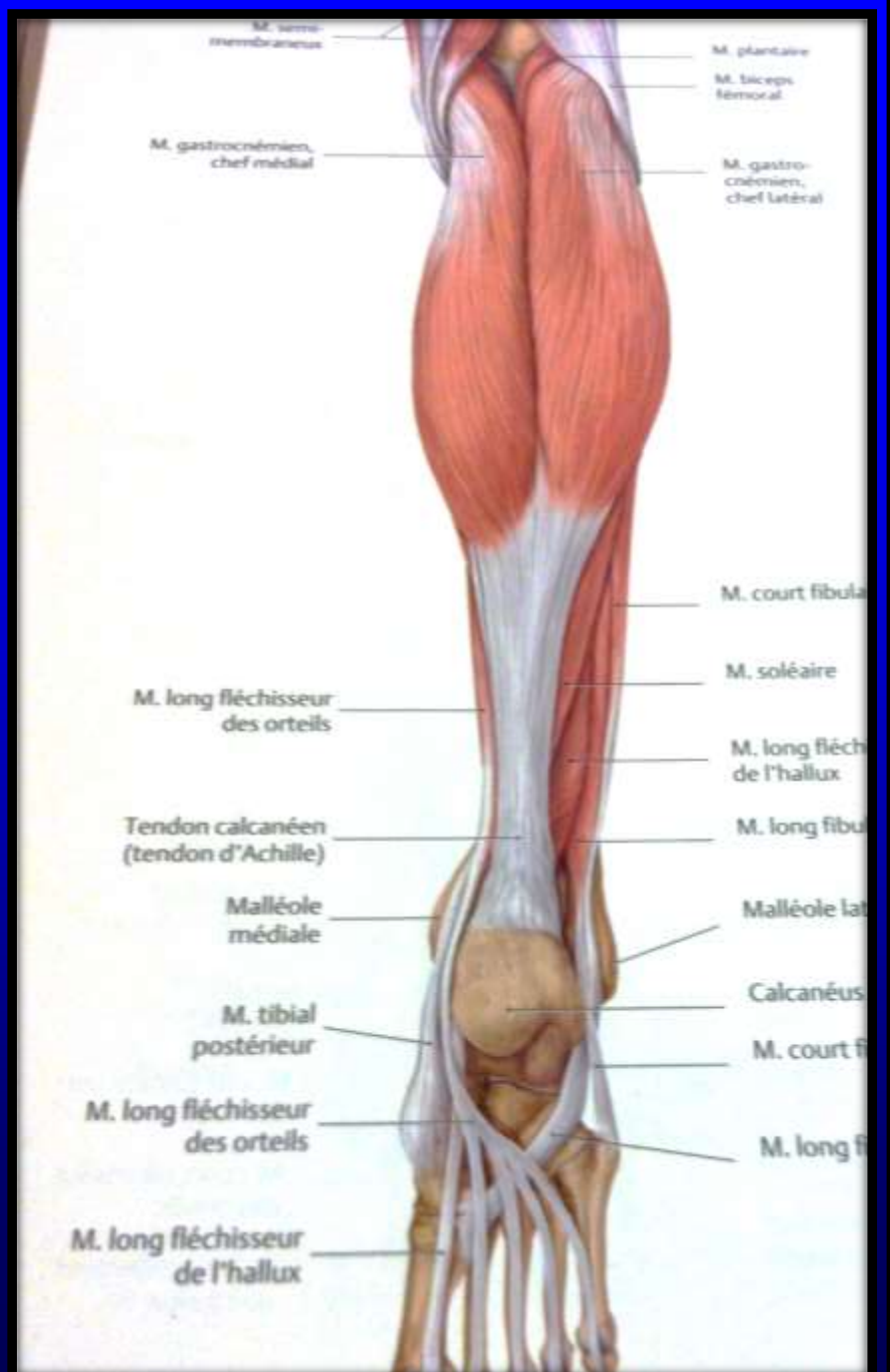
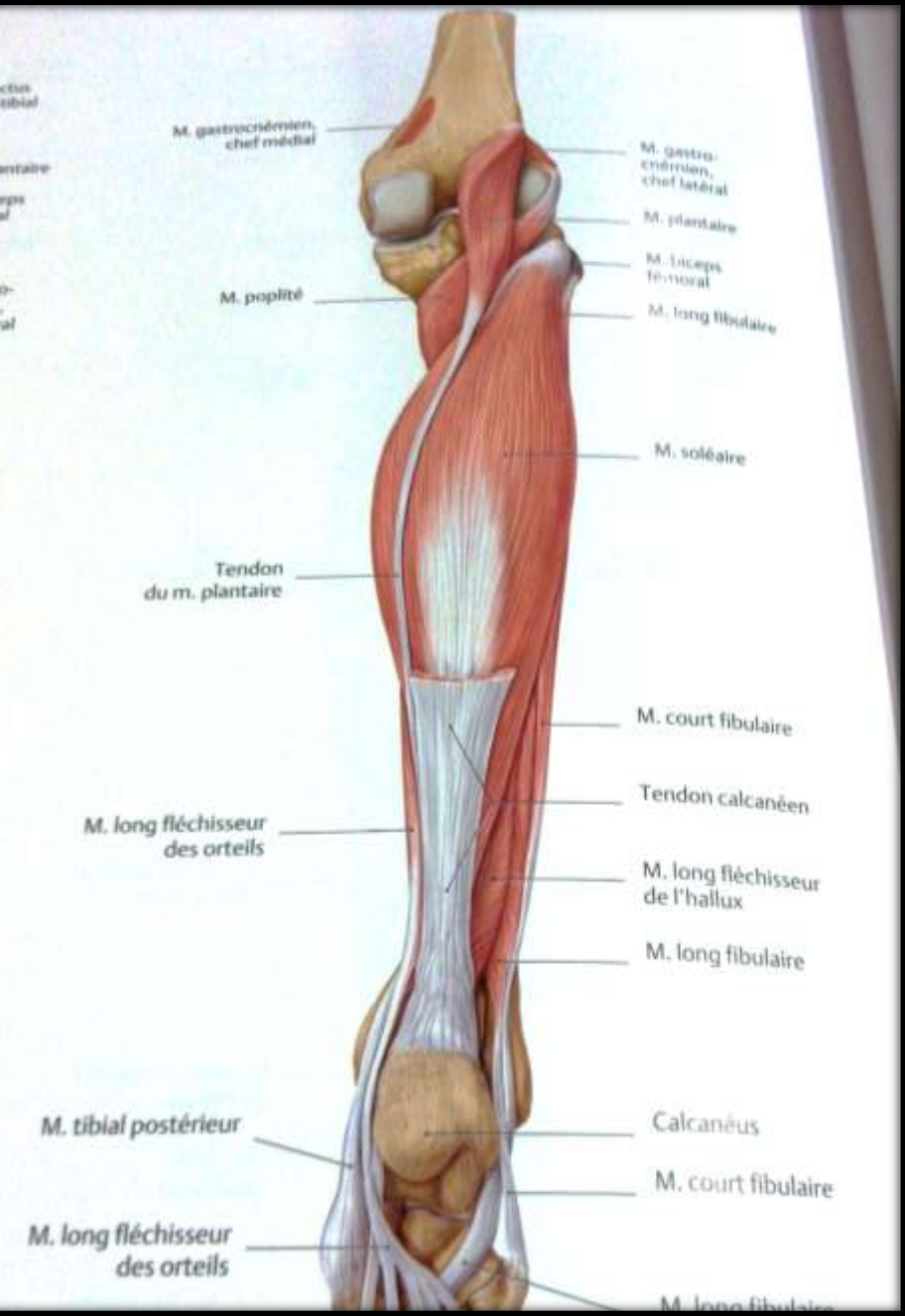
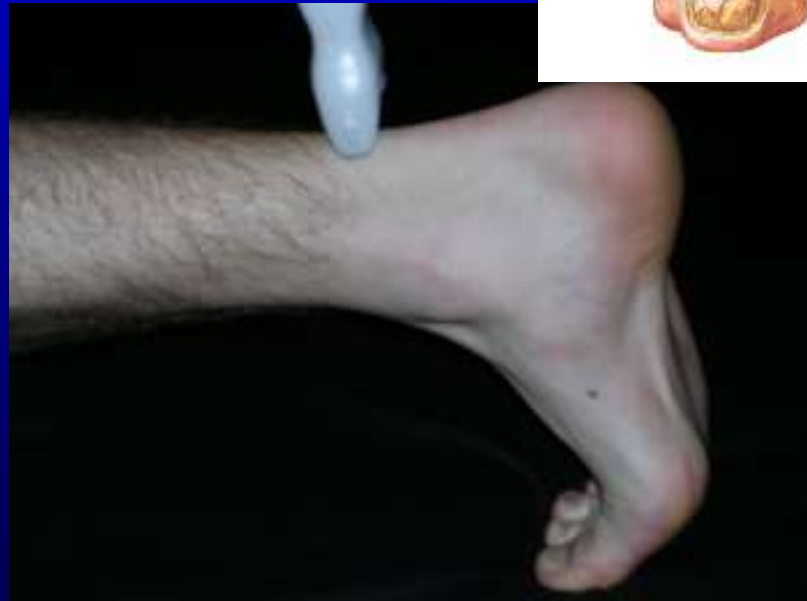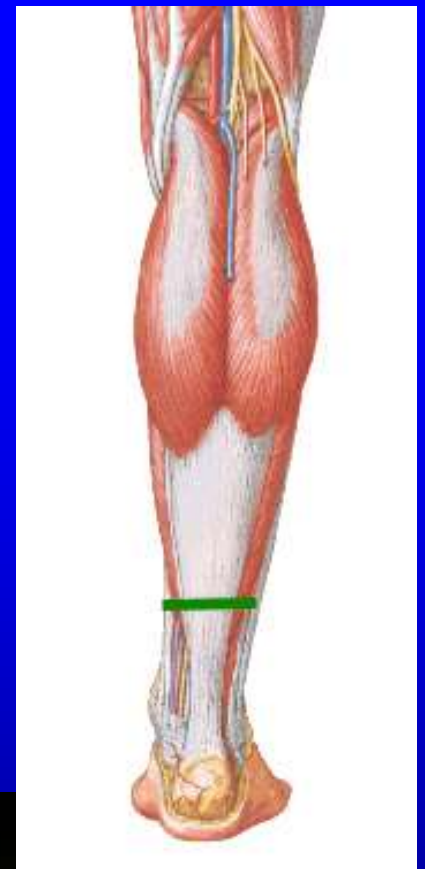

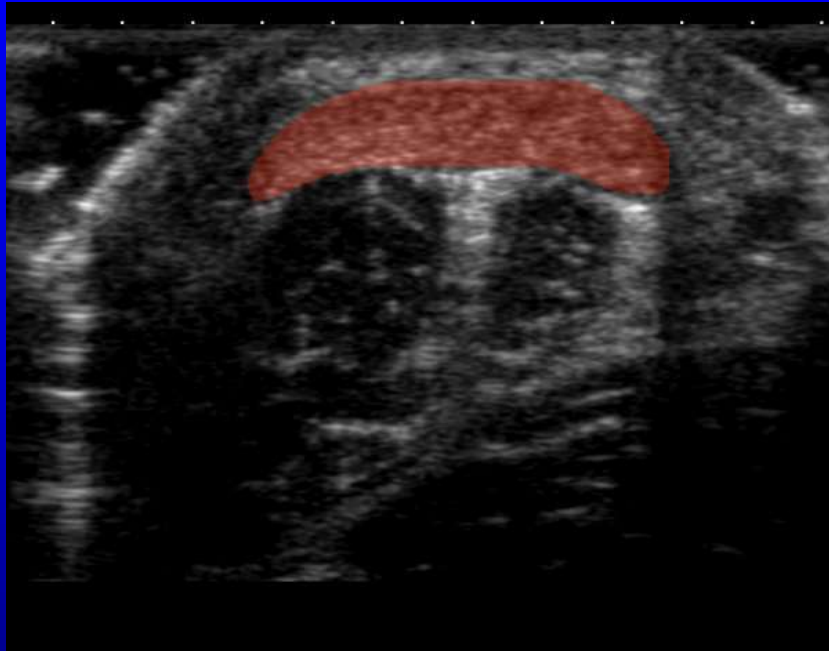
# Le tendon d'Achille et annexes

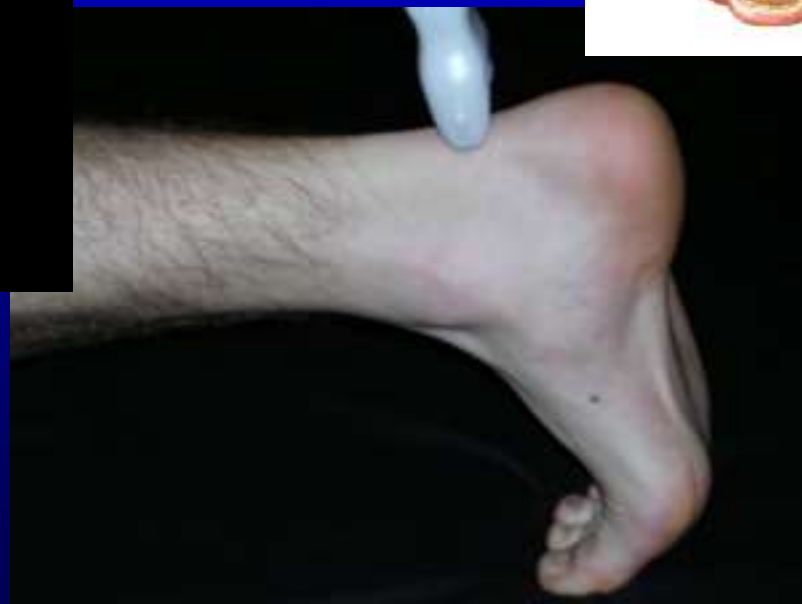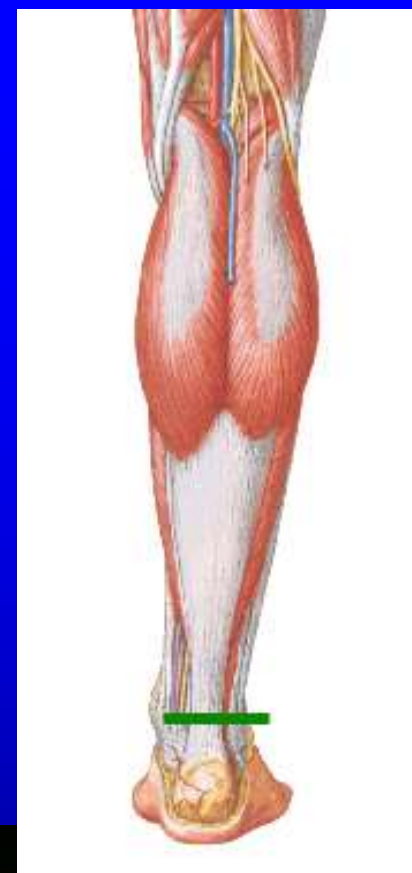
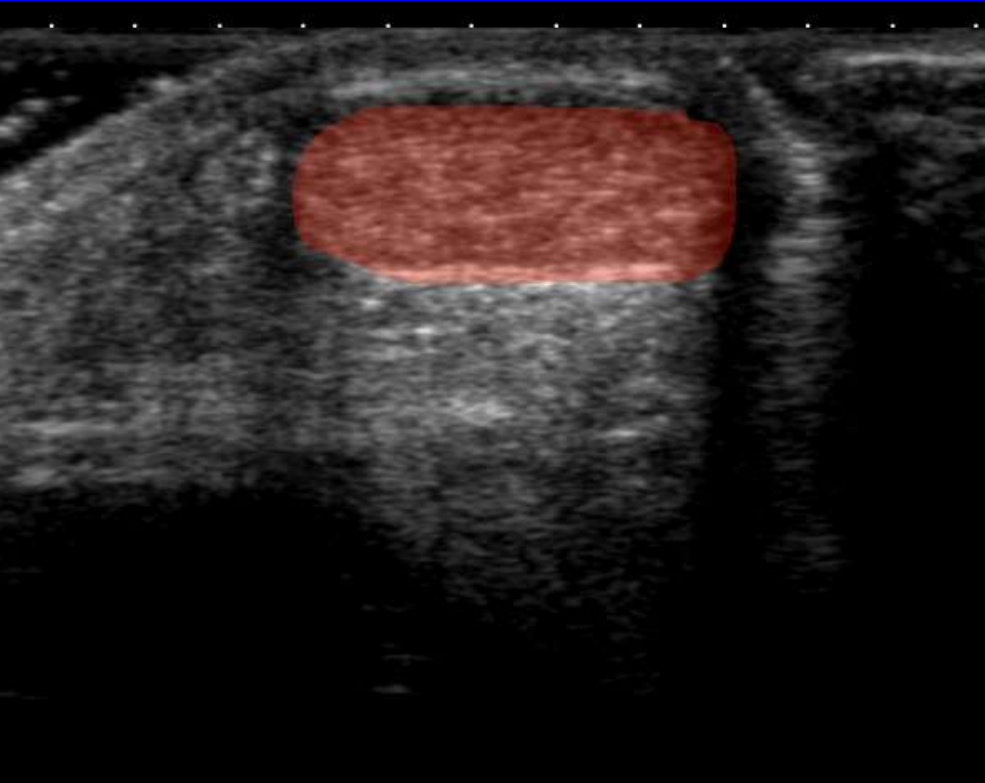
Dr Ivan PROTHOY  
Polyclinique des Alpes du Sud  
GAP



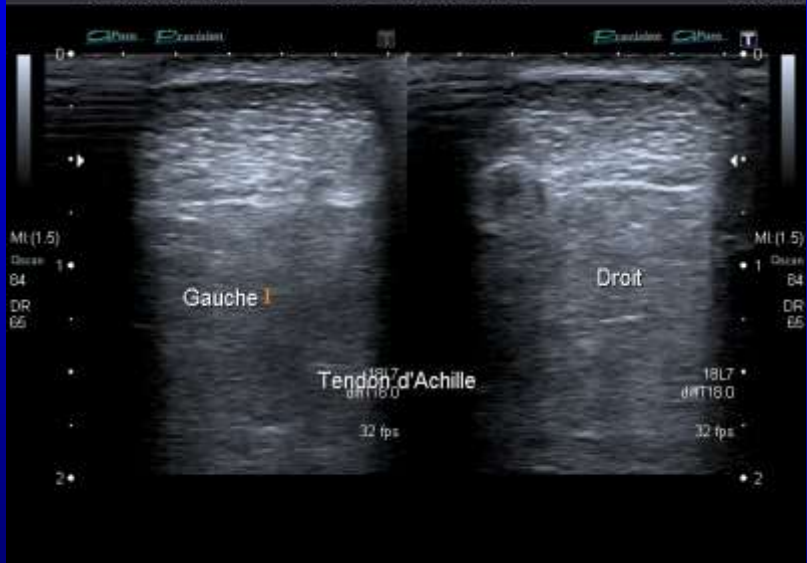# Echo Achille



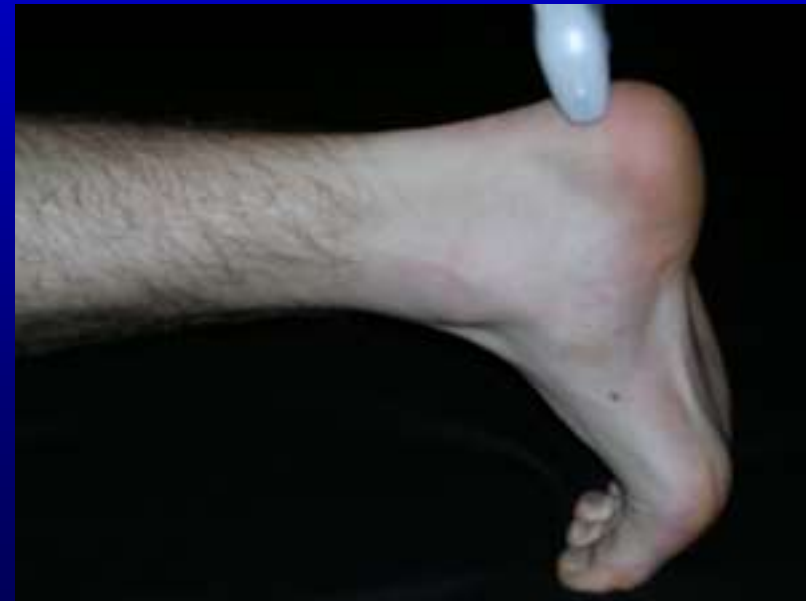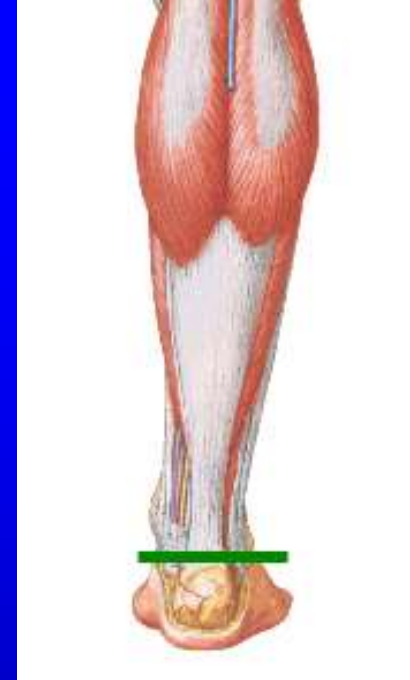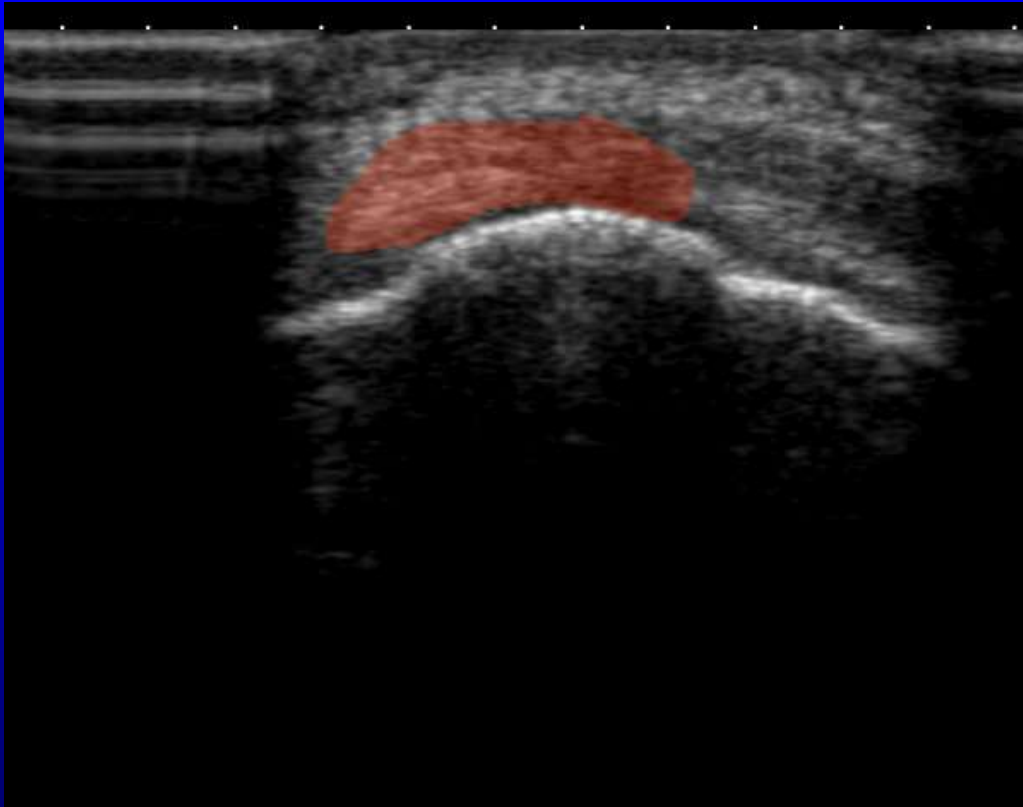
# Echo Achille



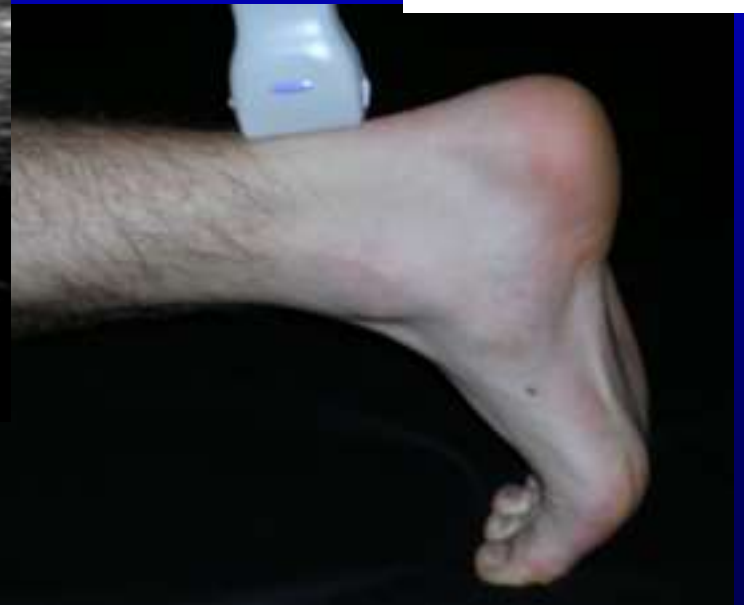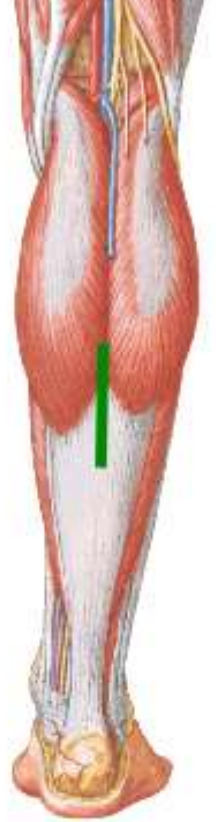
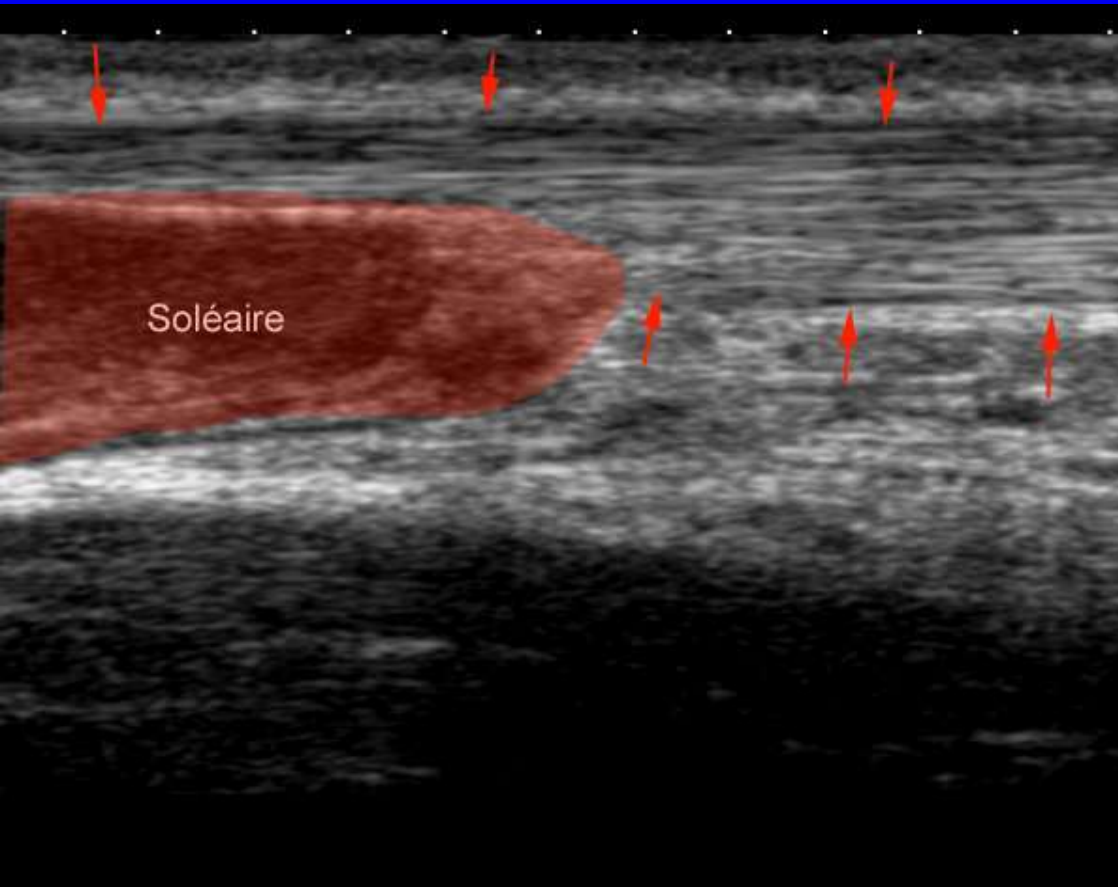
TOSHIBA ADDA COLETTE-- - 0 19.3.2012  
Dr PROTHOY Ivan - OPE - MAIN CHEVILLE 16.30.28



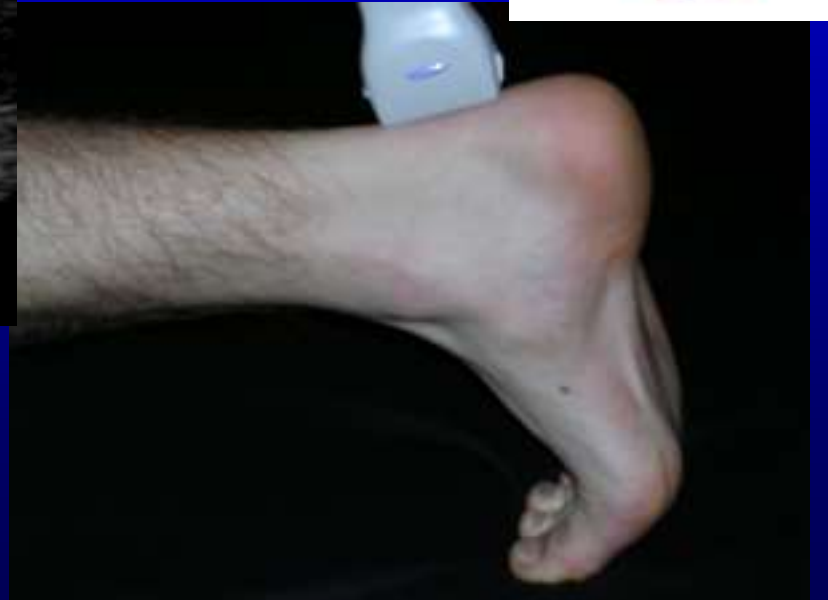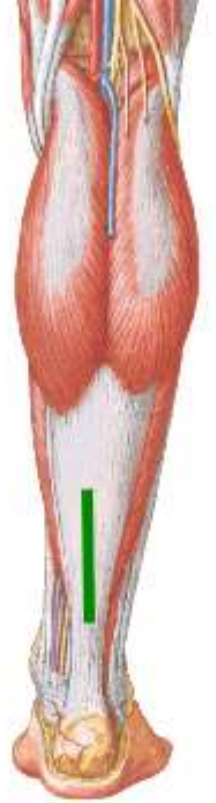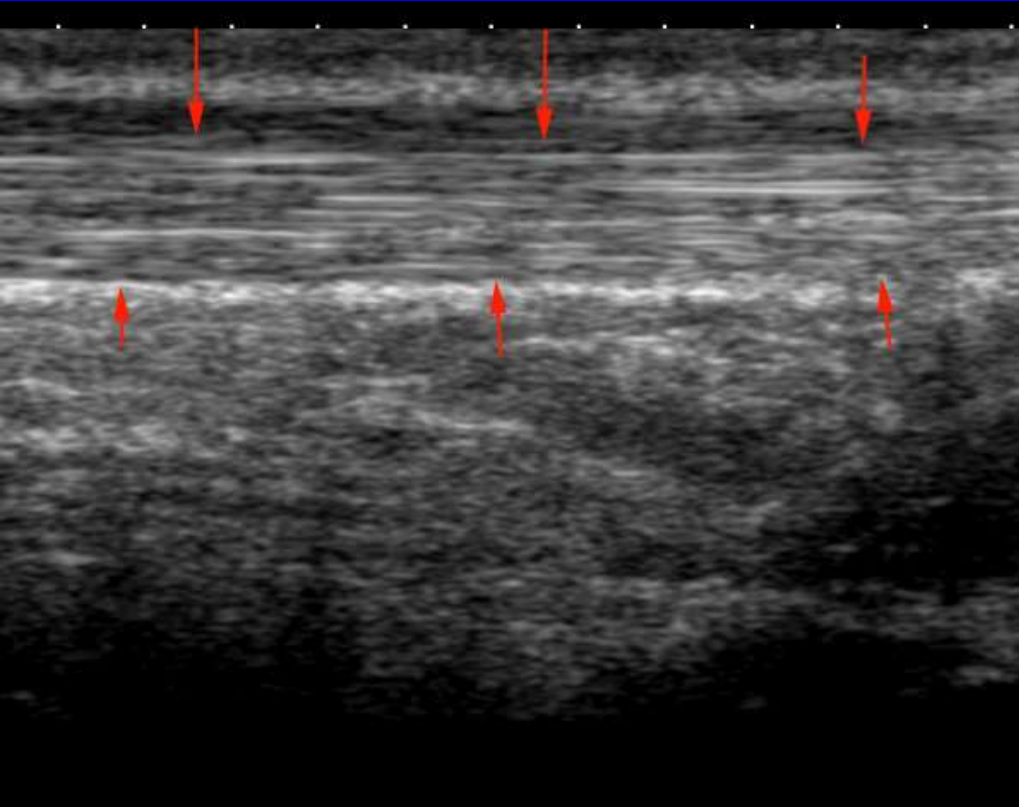
# Echo Achille

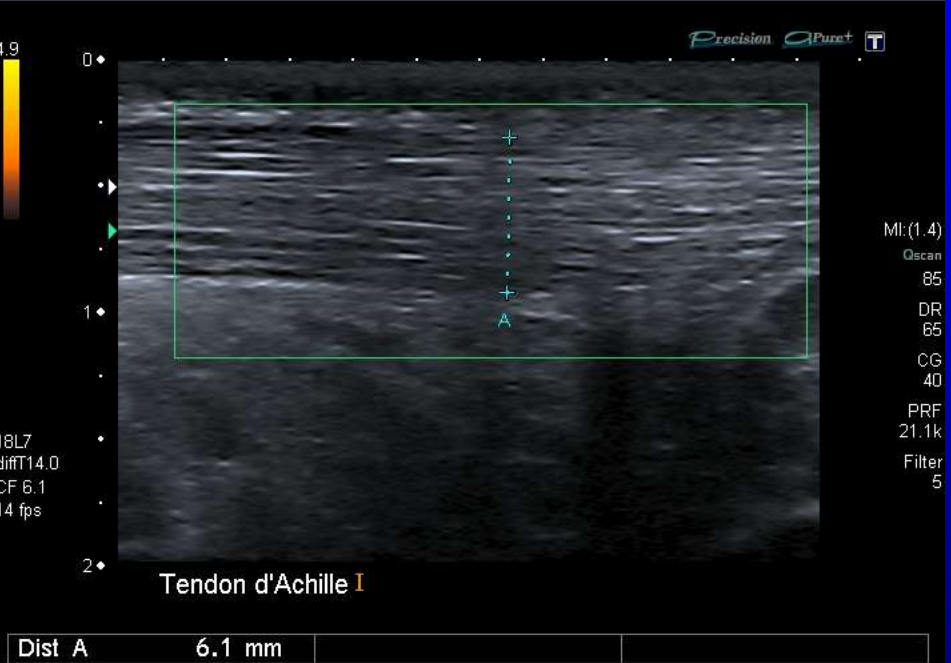


# Echo Achille

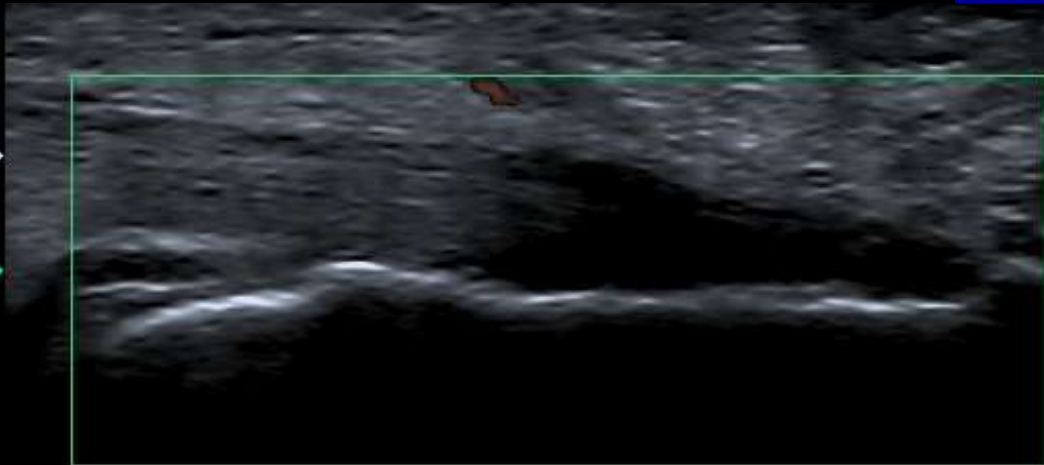
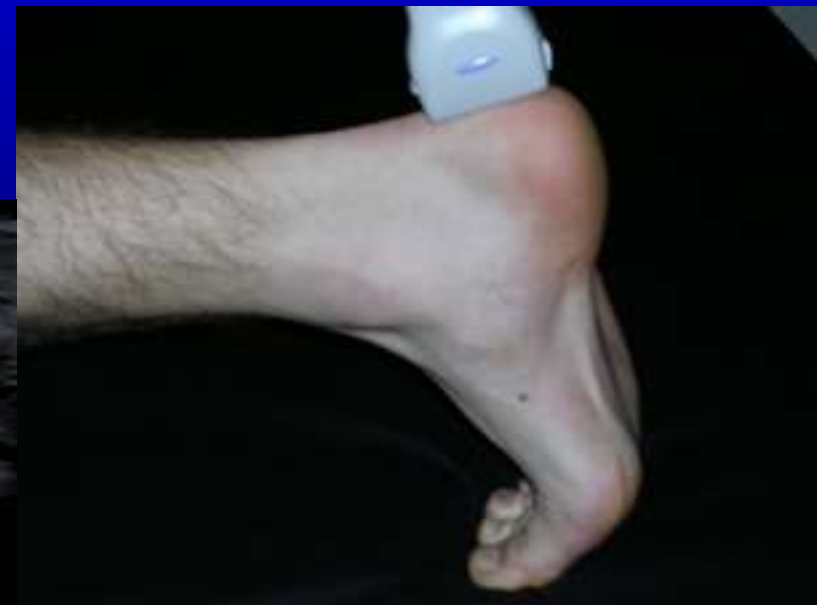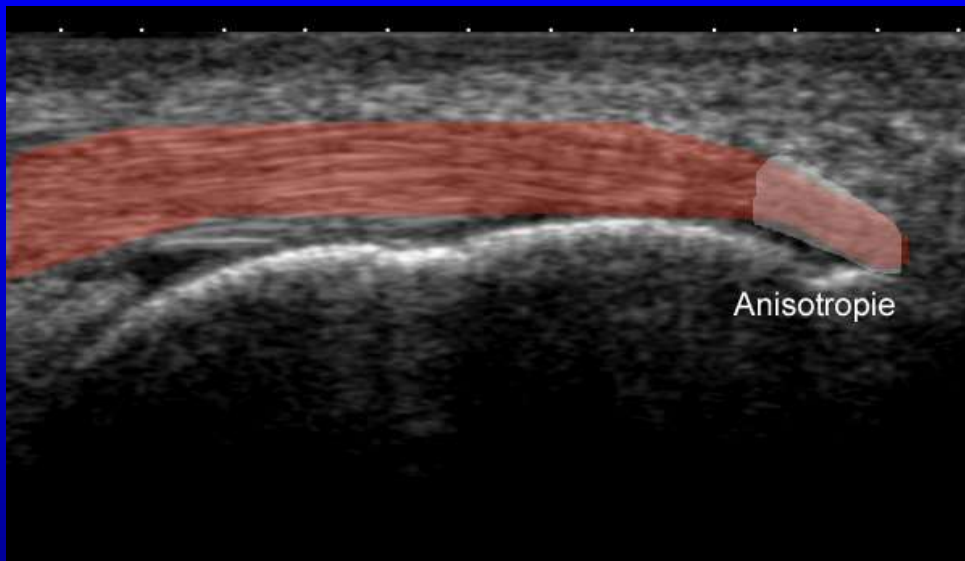

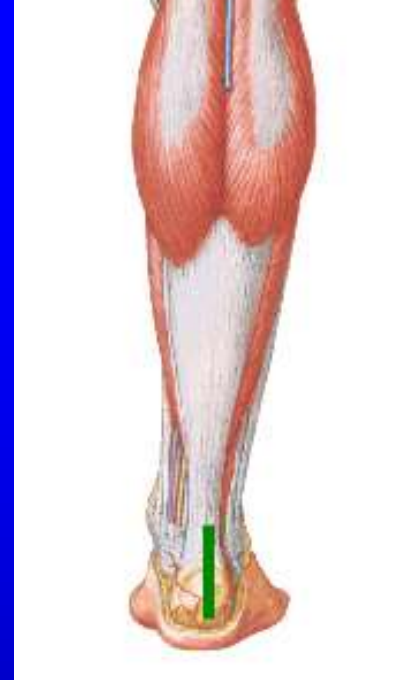
# Echo Achille





# Echo Achille



Precision Pure+ T

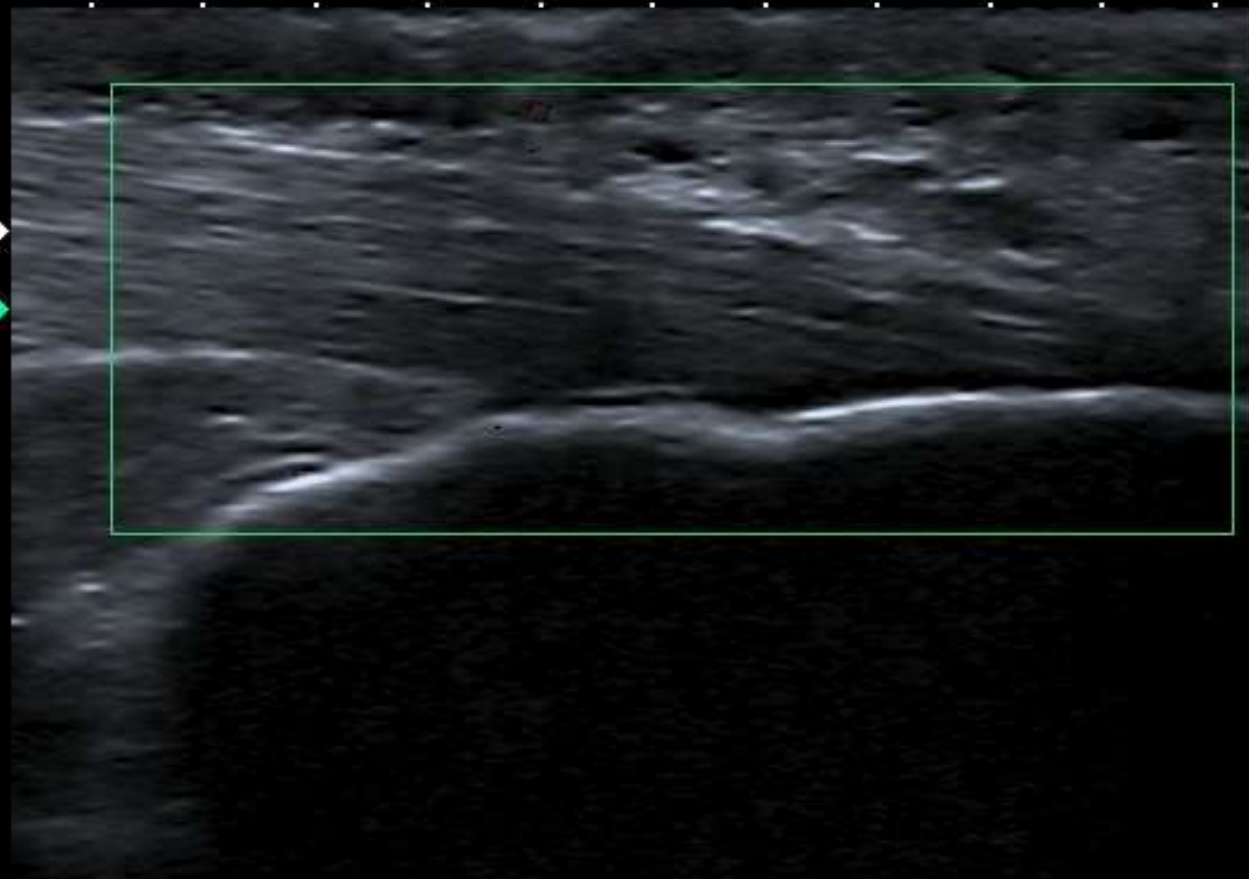
4.9



0

1

2



18L7  
diffT14.0  
CF 6.1  
14 fps

MI: (1.4)

Gscan

85

DR

65

CG

40

PRF

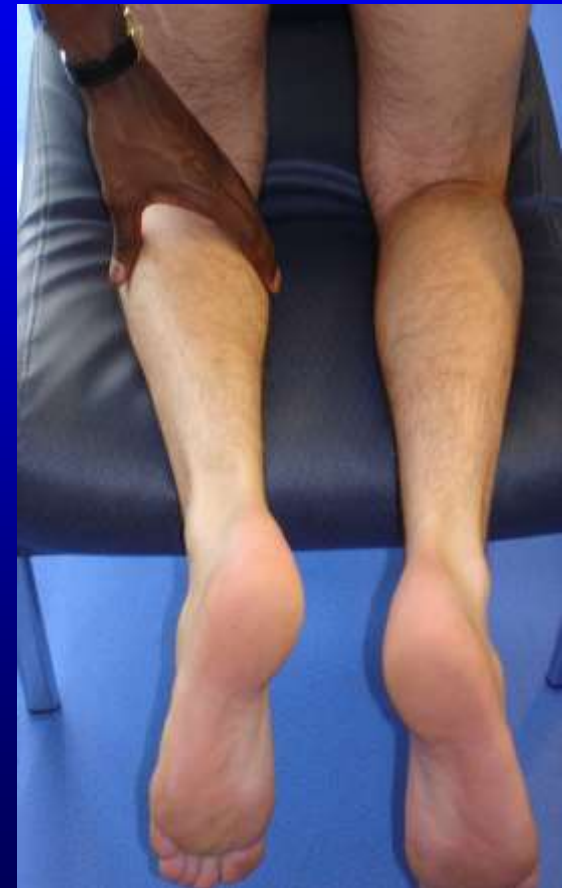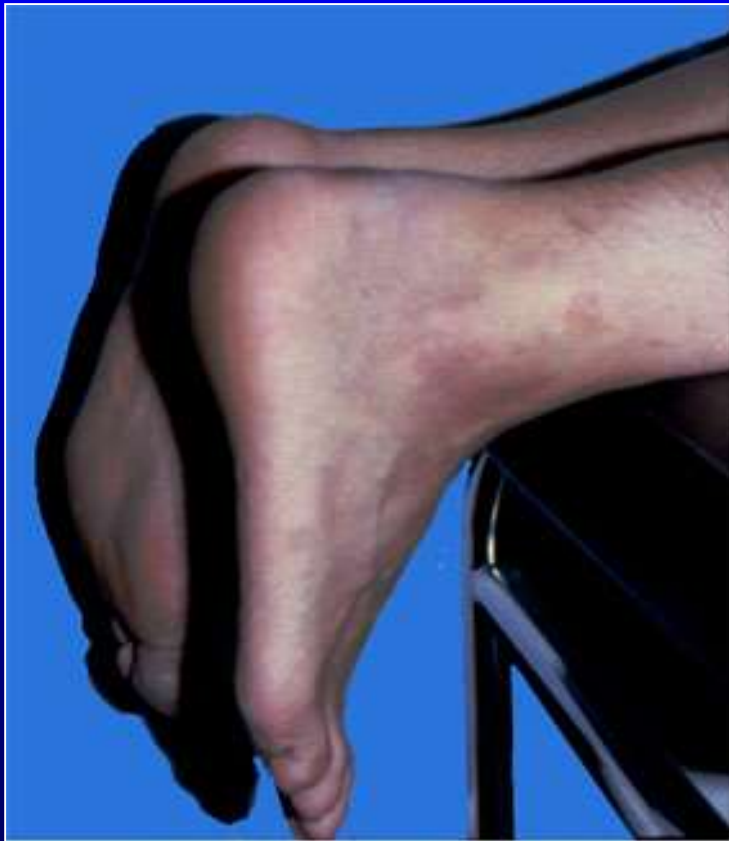21.1k

Filter

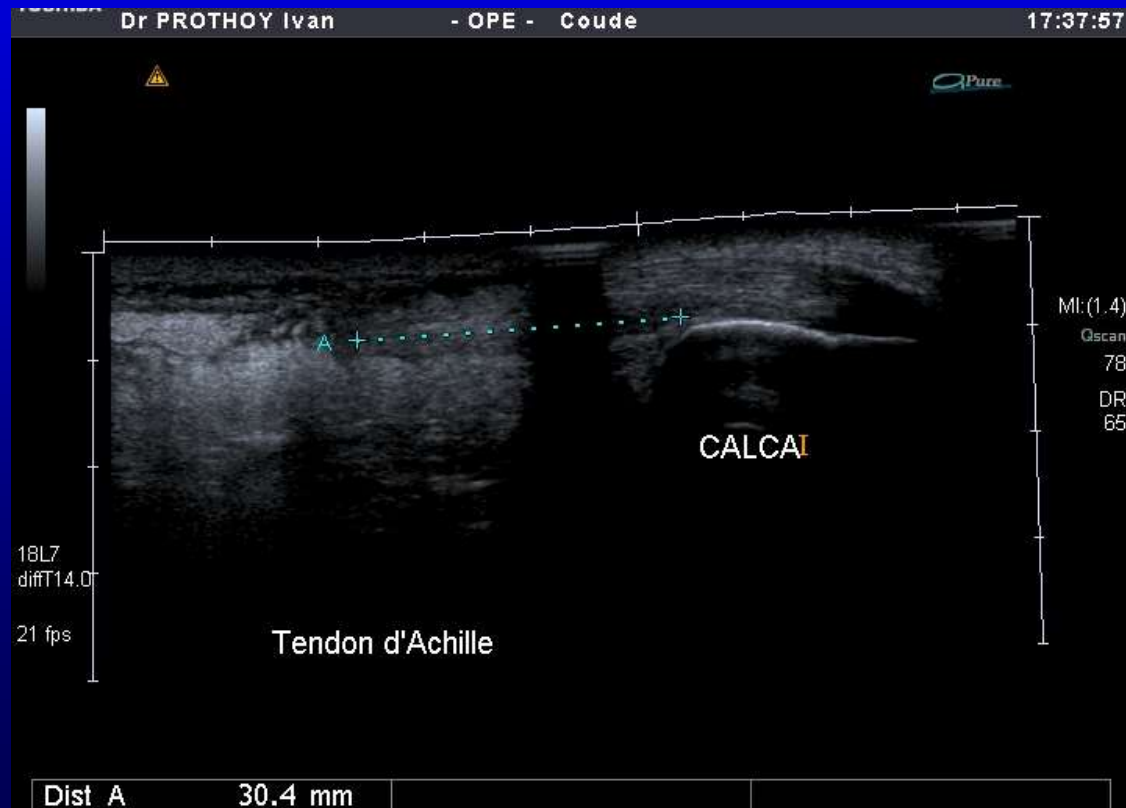
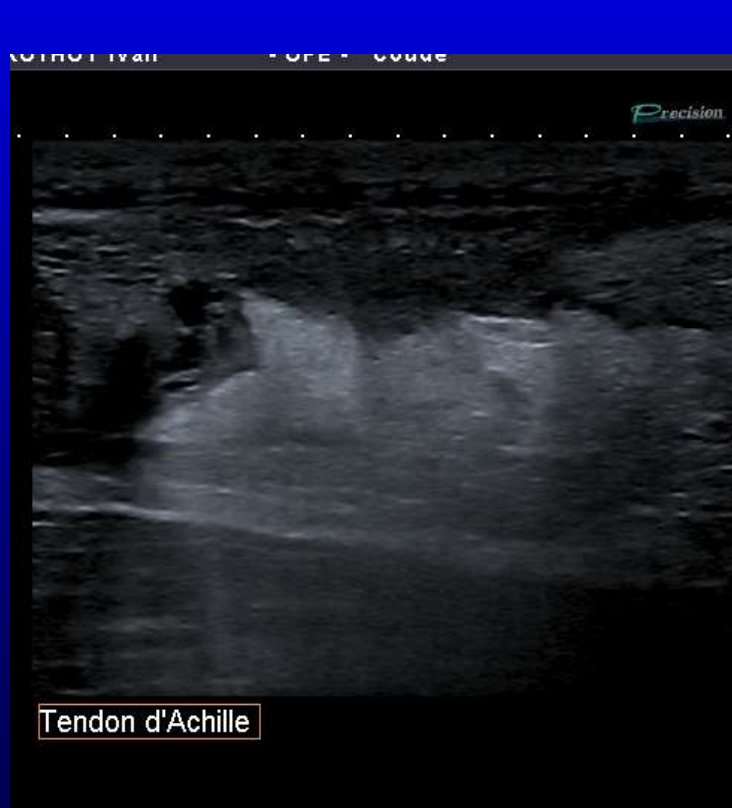5

Tendon d'Achille I

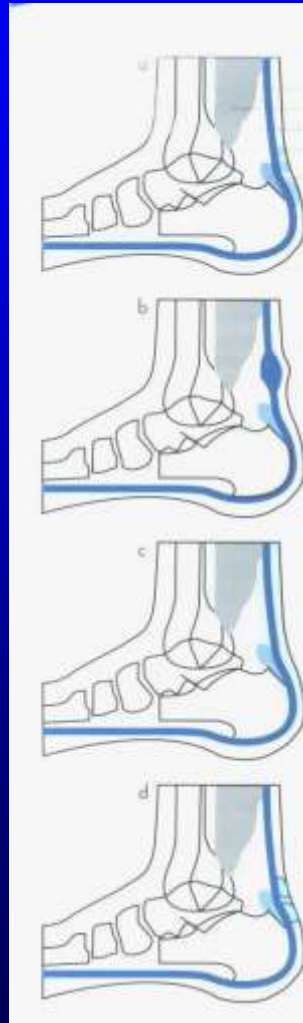# Rupture d'Achille: l'essentiel



# Rupture d'Achille

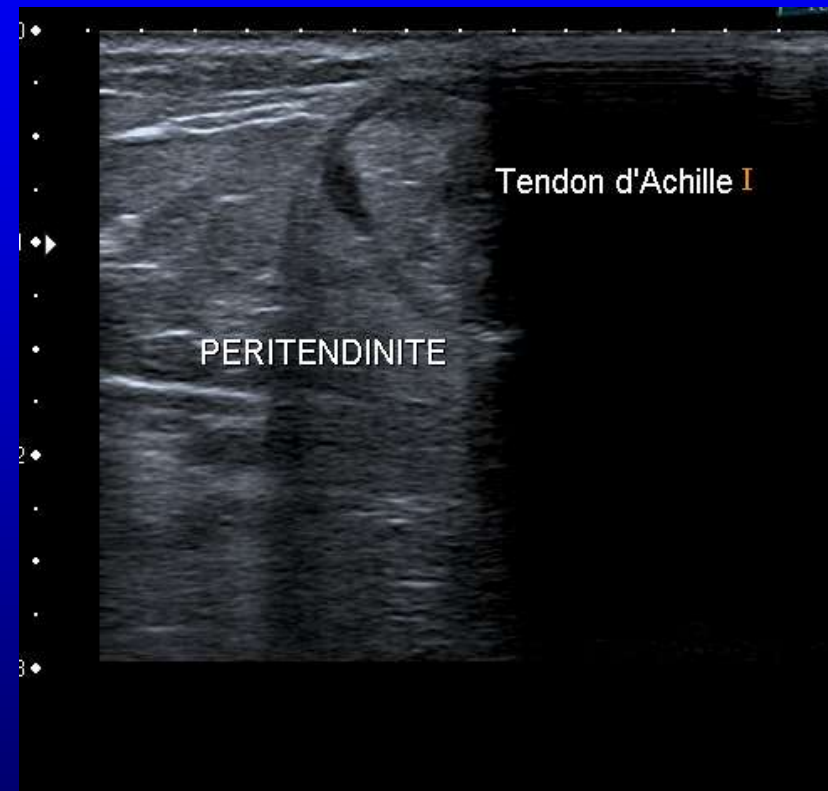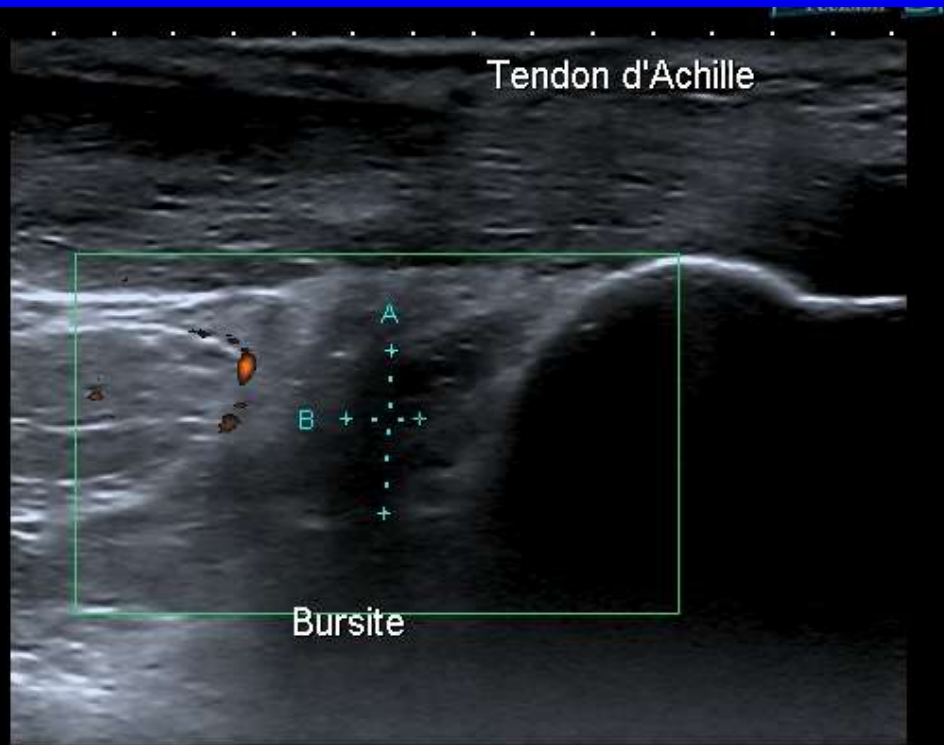


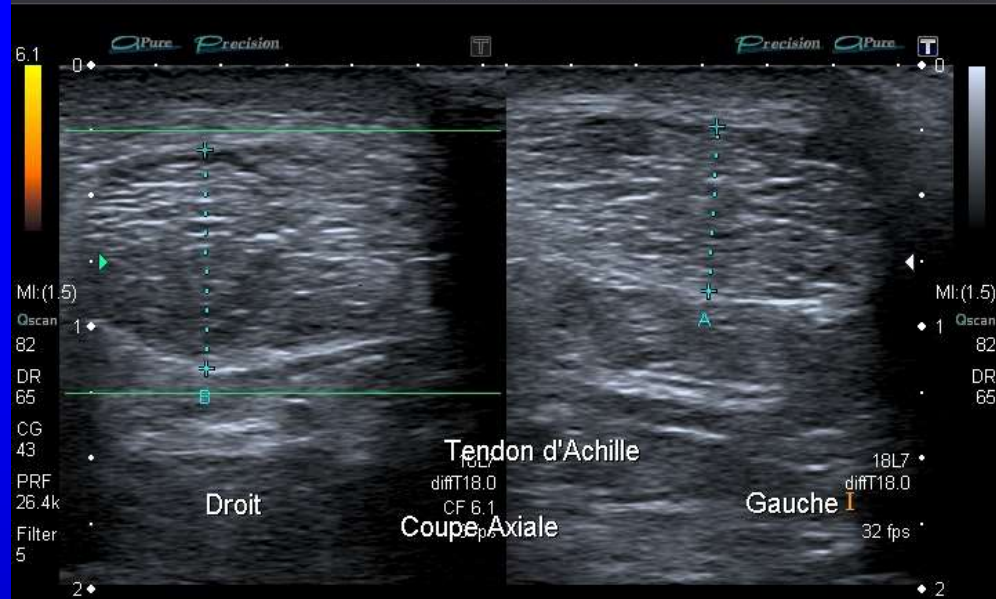
## Exemple de tendinopathies: formes cliniques au tendon d'Achille



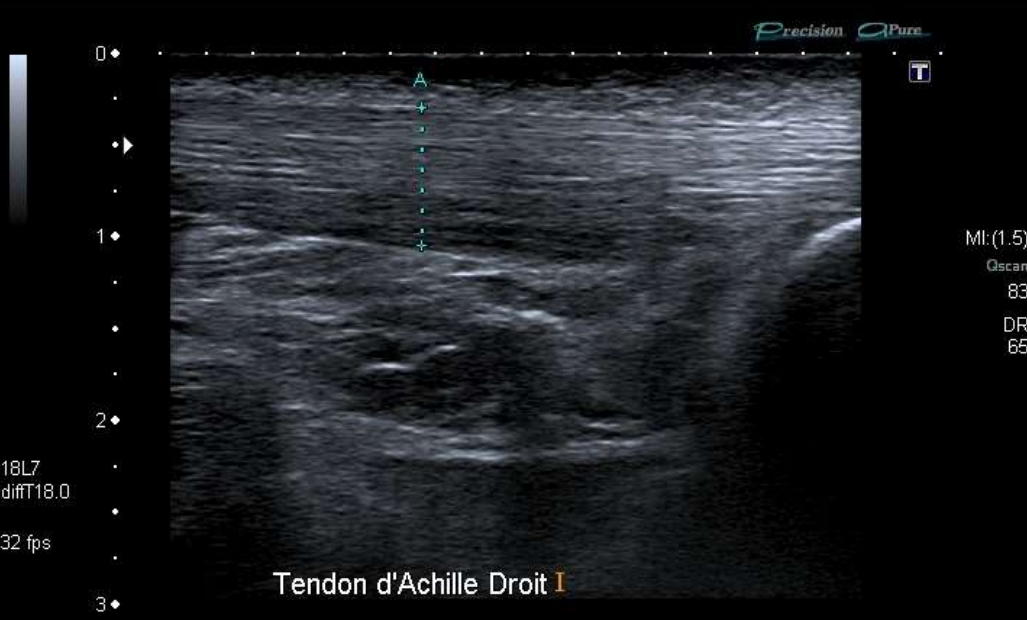
- Vue de profil d'une cheville normale
- Tendinopathie nodulaire
- ténosynovite
- bursite

# Tendon d'Achille

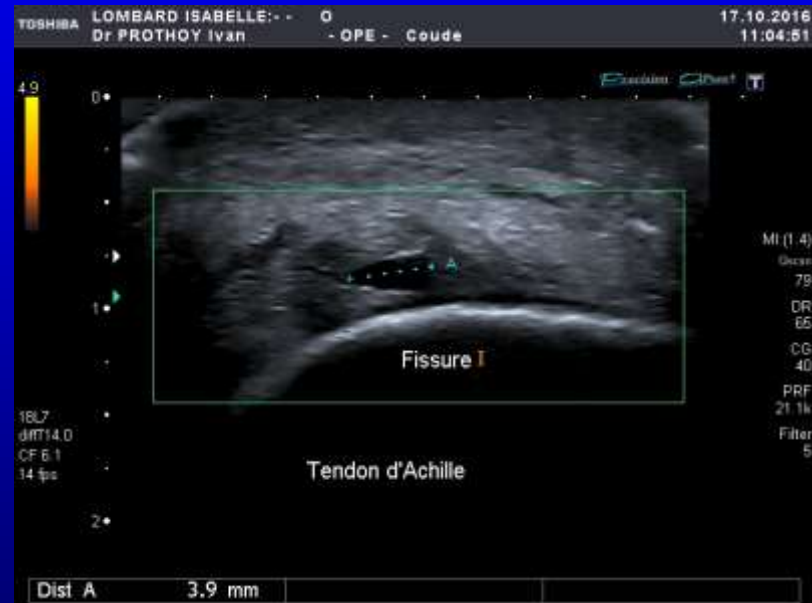
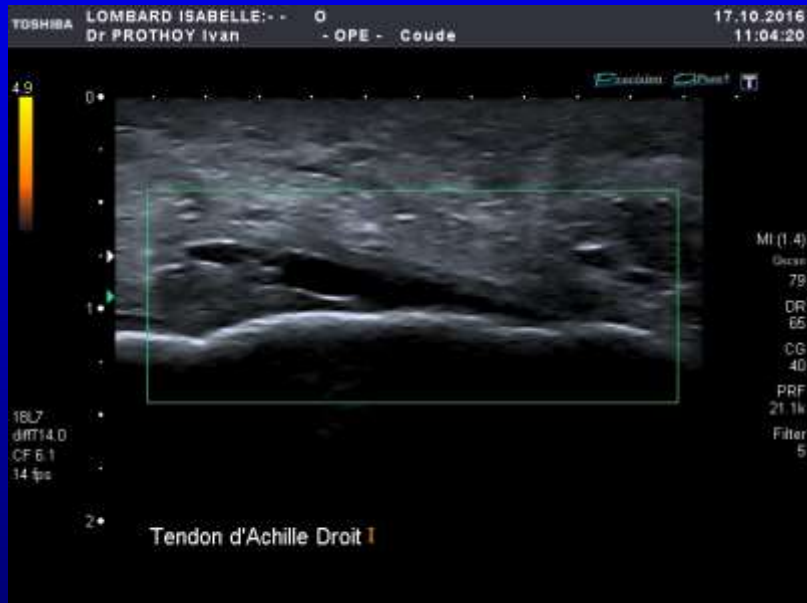


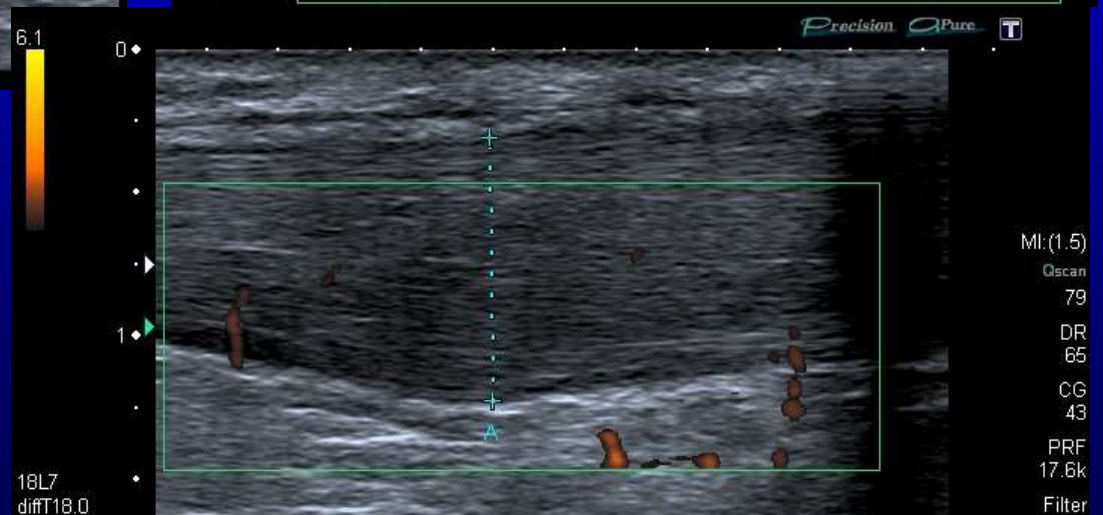
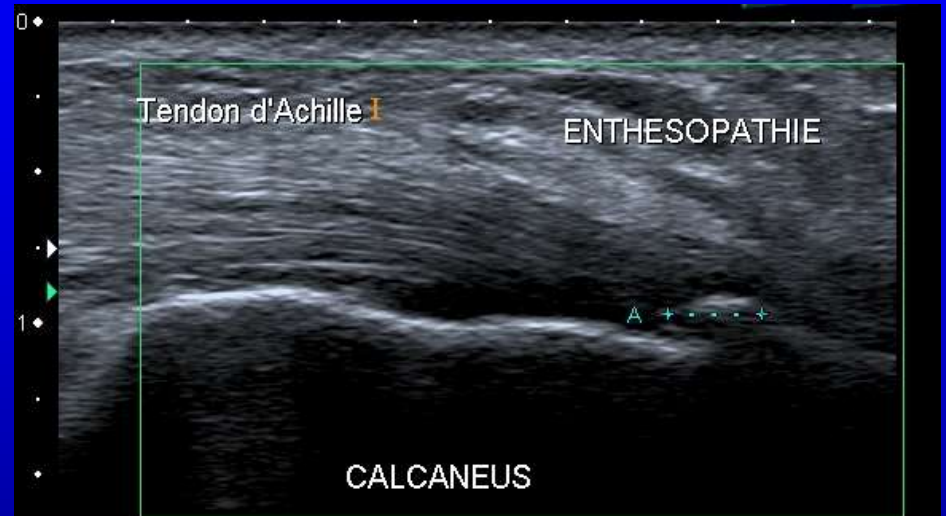
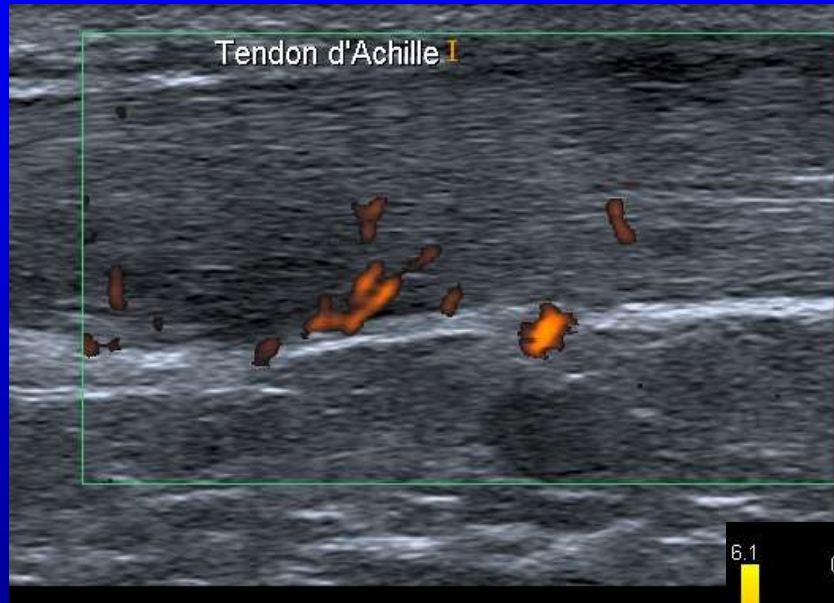Dist A	6.3 mm	Dist B	8.3 mm
--------	--------	--------	--------



Dist A	7.5 mm		
--------	--------	--	--



# Tendon d'Achille



TOSHIBA

Dr PROTHOY Ivan

- OPE - Coude

14:54:14

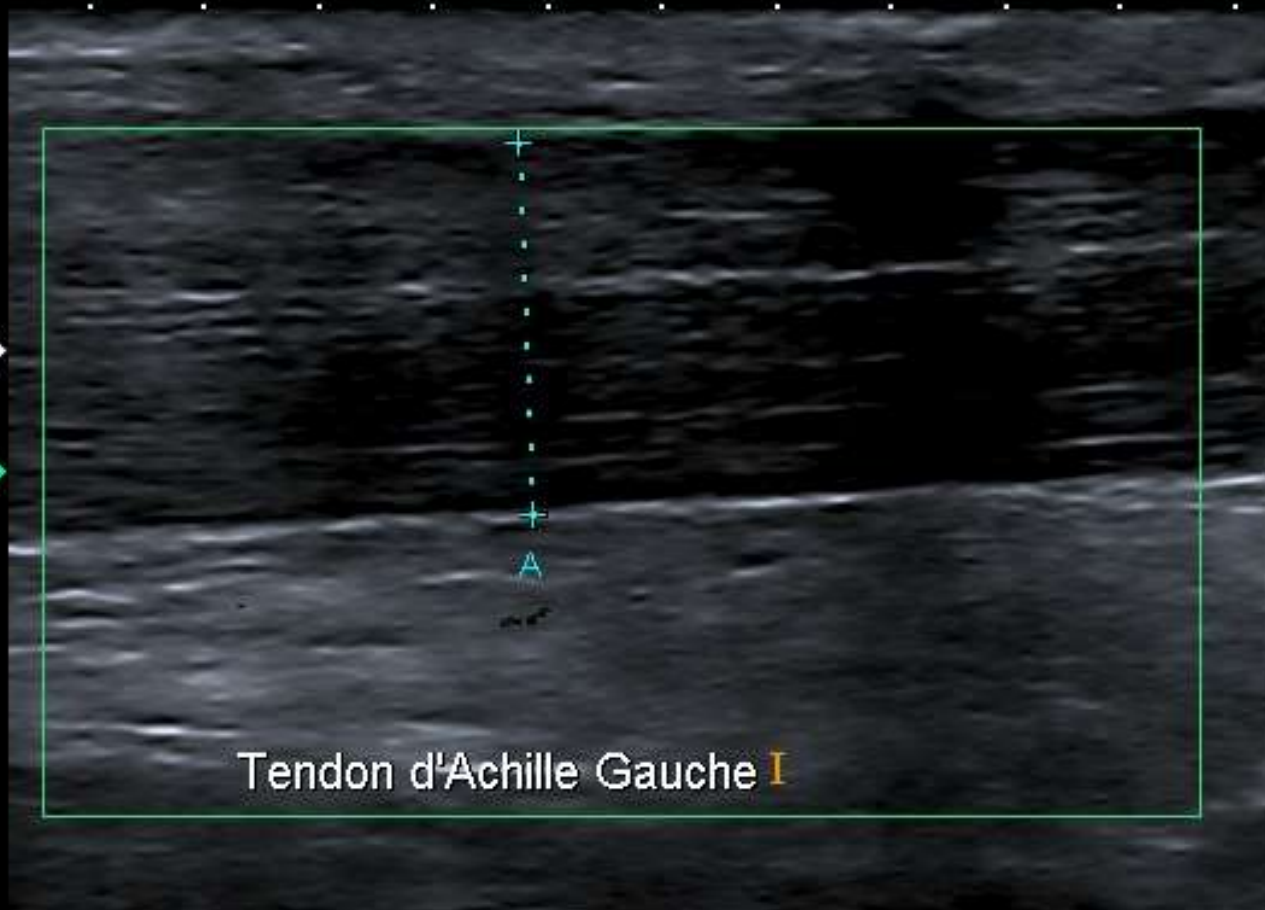
Precision Pure+ T

4.9

0

1

2



MI: (1.5)

Qscan

74

DR

65

CG

40

PRF

21.1k

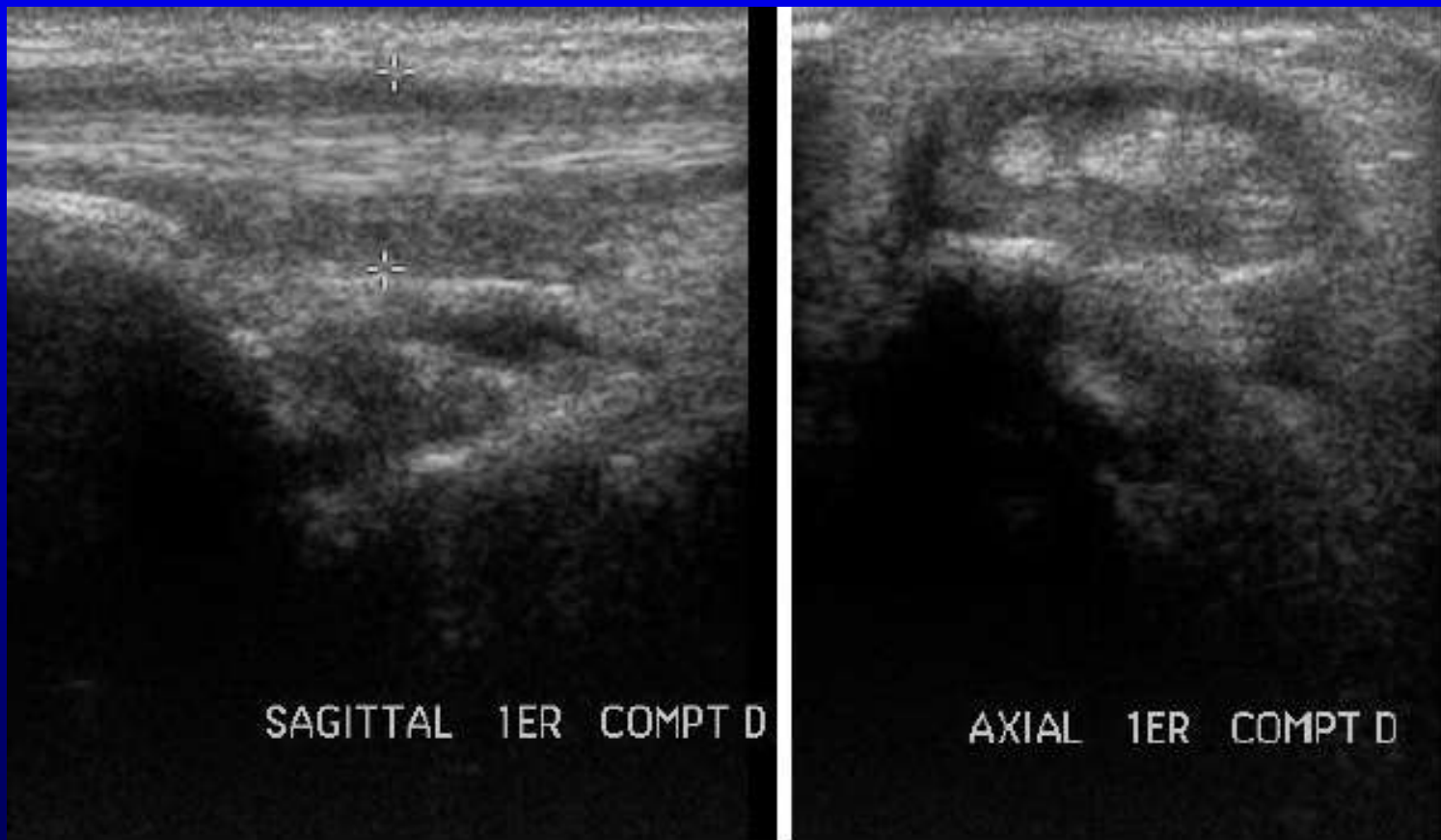
Filter

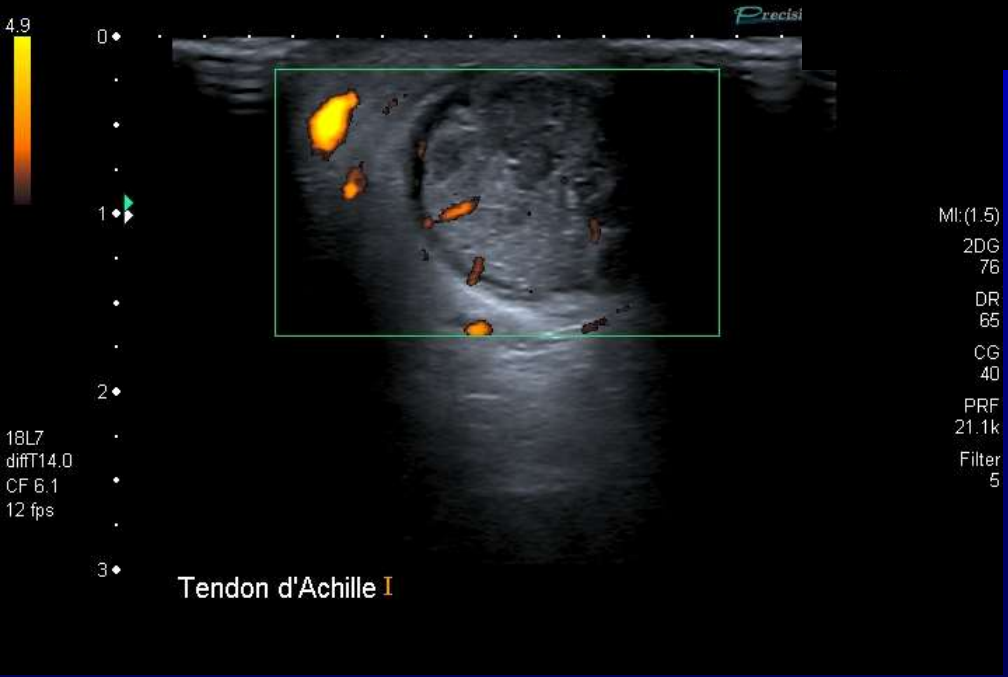
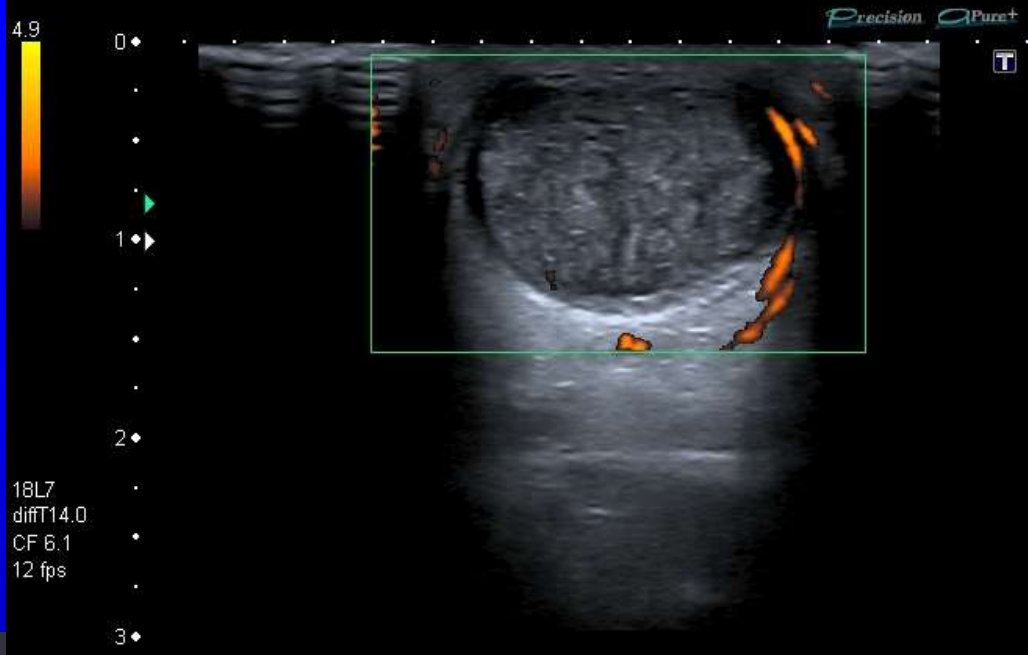
5

18L7  
diffT14.0  
CF 6.1  
12 fps

Tendon d'Achille Gauche I

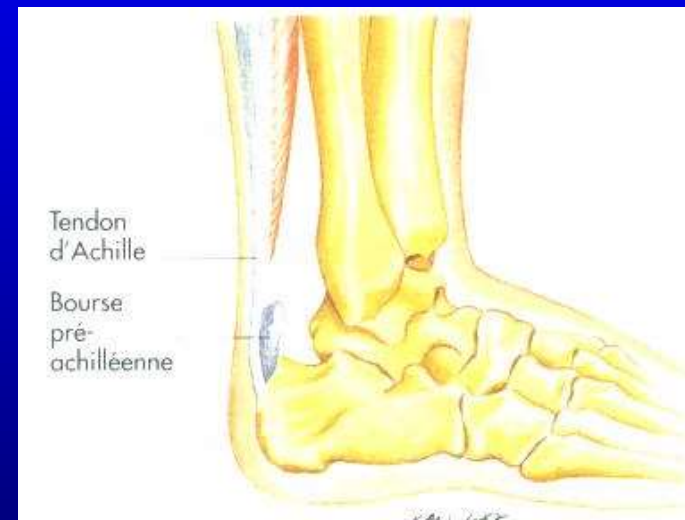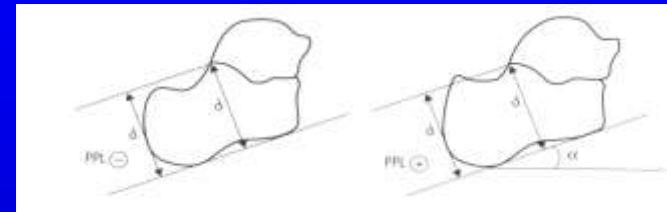
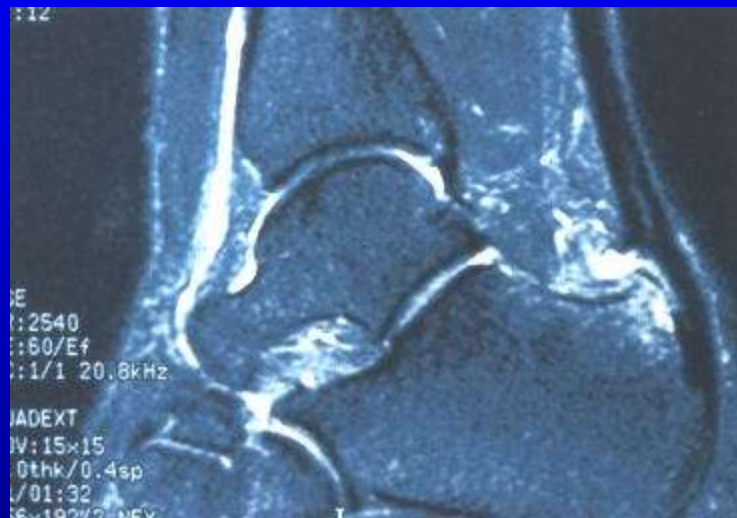# Synovite péri tendineuse (hors Achille)







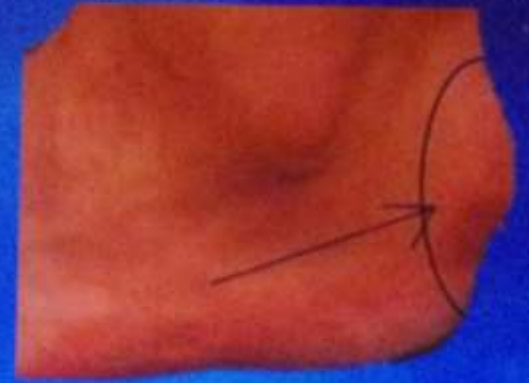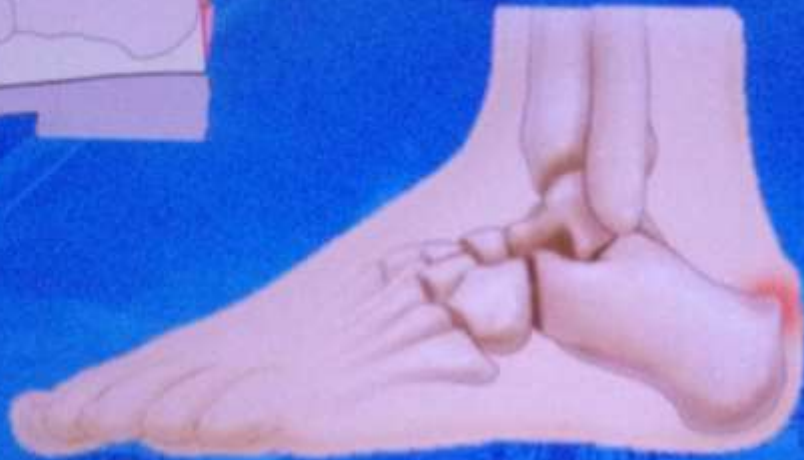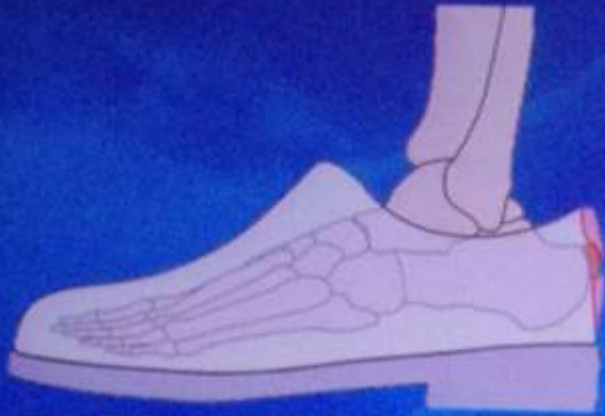# Exemple de tendinopathies

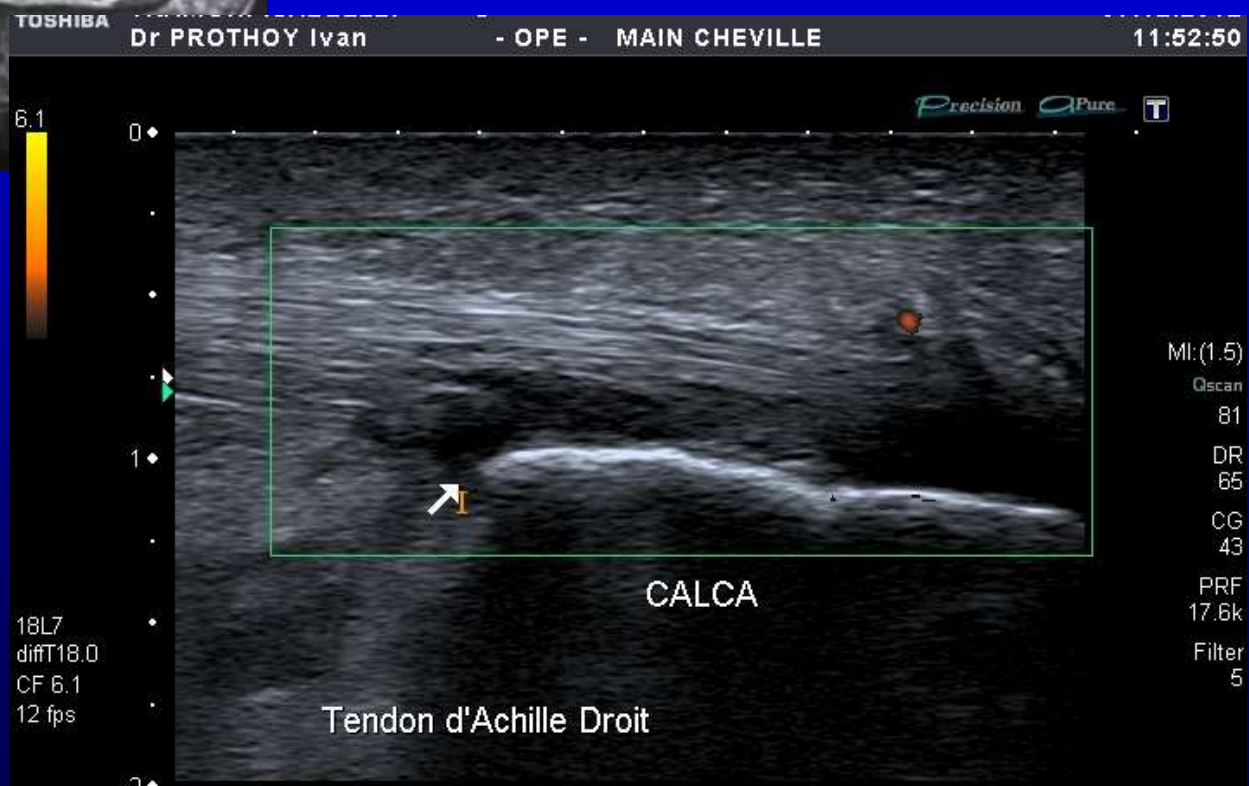
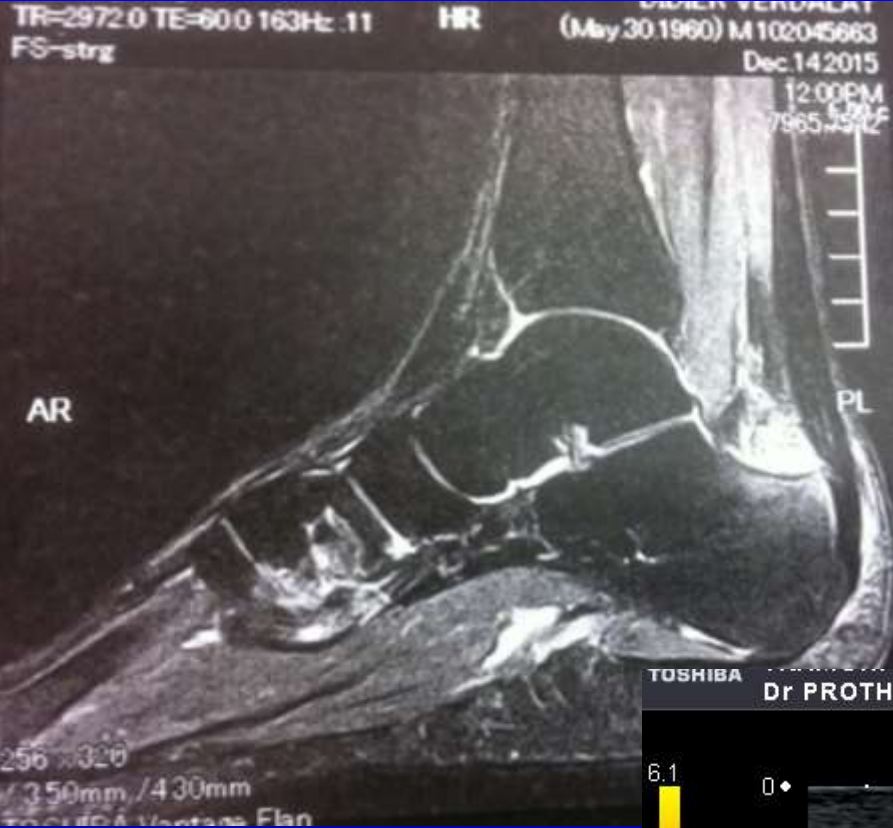

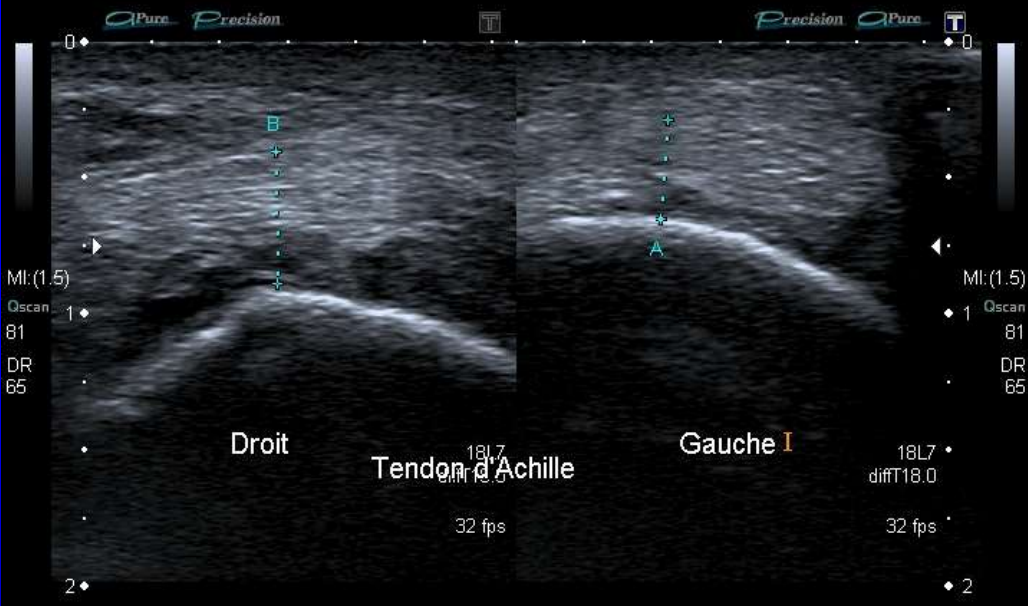
- Fissuration du tendon d'Achille+ bursite pré achilléenne

- Rappels anatomiques

# 1 – Déformation d'HAGLUND







Dist A	3.6 mm	Dist B	4.8 mm
--------	--------	--------	--------

